

Brugada and J wave patterns

The role of vectorcardiography in distinguishing them

*Prof. Carlos Alberto Pastore, MD, PhD, FESC; Dr. Nelson Samesima, MD, PhD
Clinical Unit of Electrocardiography - Heart Institute (InCor) – Hospital das
Clínicas da Faculdade de Medicina, Universidade de São Paulo, Brazil*

Reference: C.A. Pastore et al. / Journal of Electrocardiology 2016;49:439–445

J point alterations (changes in the final portion of the QRS complex and beginning of the ST-segment) were thoroughly described for several pathologies. However, the underlying mechanisms of such alterations can either have an autonomic origin, or be the result of dysfunctional ion channels, or even reflect disturbances in the electrical conduction of impulses. Careful observation of electrocardiographic patterns and knowledge of the contributions from vectorcardiography can lead to a qualified and accurate distinction of the many reasons that result in a J point alteration. This distinction can be made by performing a regional analysis of alterations in the vectorcardiographic loops.

Both the Brugada syndrome (BrS) and J-wave ECG patterns show J-point and ST-segment alterations which are critical for determining phenotype and prognosis. In most cases, BrS and early repolarization (ER) have clearly distinct ECGs.

Those cellular alterations occurring in the epicardial region of the right ventricle in type I pattern of Brugada syndrome (BrS) are seen in leads V1, V2 and V3 (fig.1A), while the ones caused by the ECG pattern of early repolarization (ER) are most commonly present in the anterior wall of the left ventricle, observed in leads V3 to V6 (fig.1B).

However, in a few cases the early repolarization pattern is also found in the anteroseptal region (V1–V3) of the 12-lead ECG (fig.1C), with commonly misleading diagnosis, requiring other tools to differentiate them.

The vectorcardiogram is a classical tool to analyze, from a spatial point of view, the electrical phenomena occurring in the heart, in the frontal, transverse and sagittal planes. The spatial orientation of the resulting cardiac vectors allows for better centralization of the heart.

Here we define, both qualitatively and quantitatively, the vectorcardiographic patterns of the QRS loops, J-points and ST-segments in the classic Brugada syndrome and early repolarization ECG configurations in two study groups. After that, we present controversial ECGs (a third group) illustrating the usefulness of the vectorcardiogram in atypical cases.

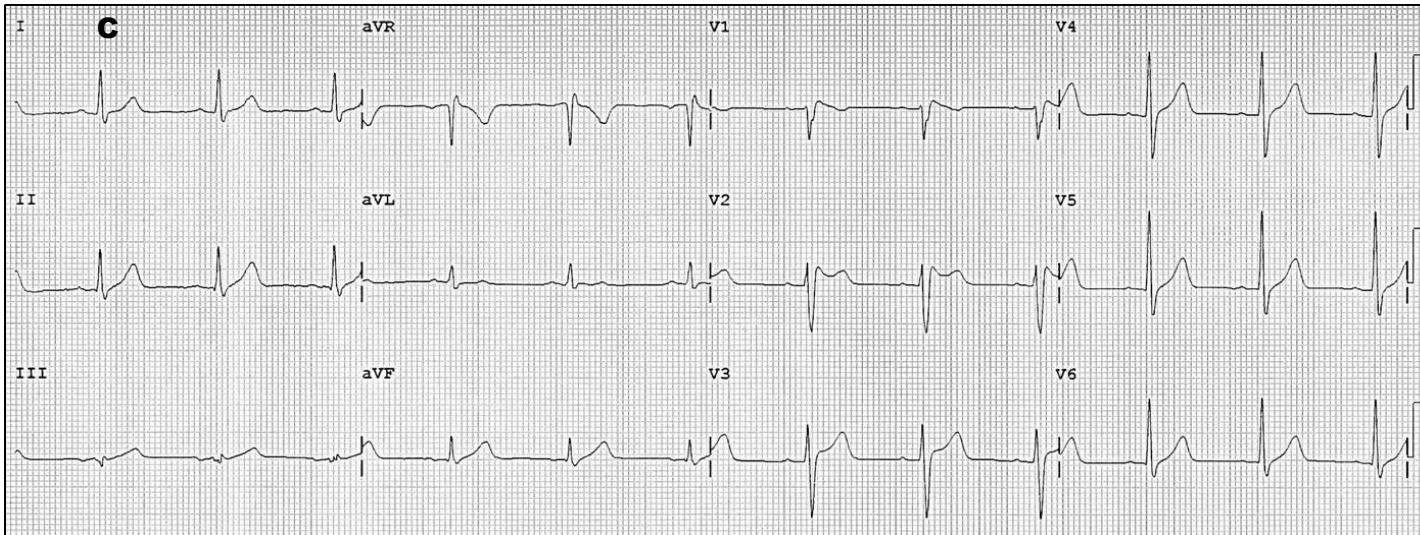
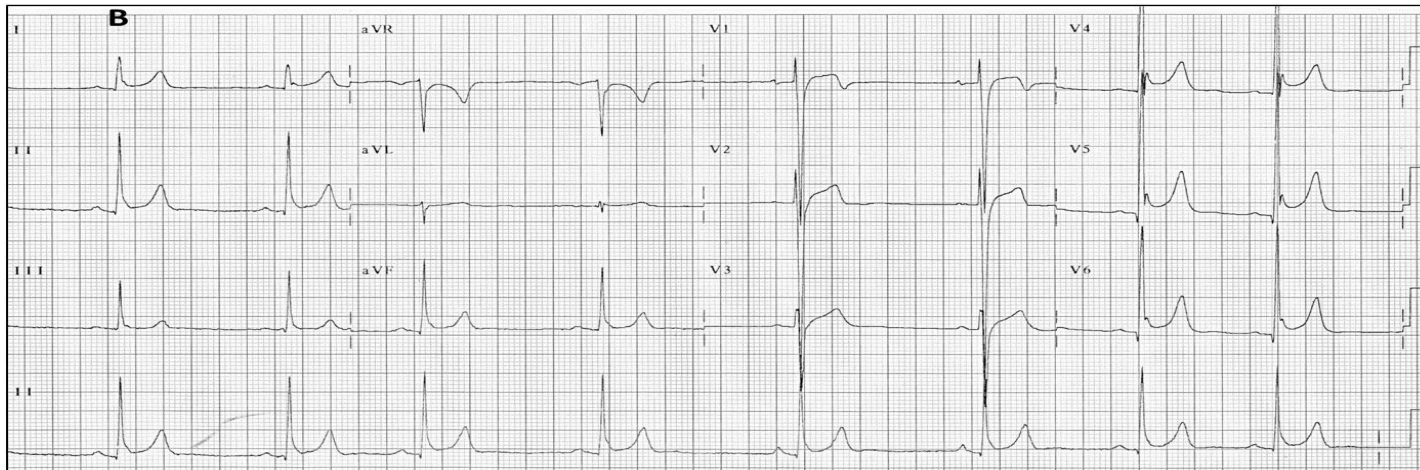
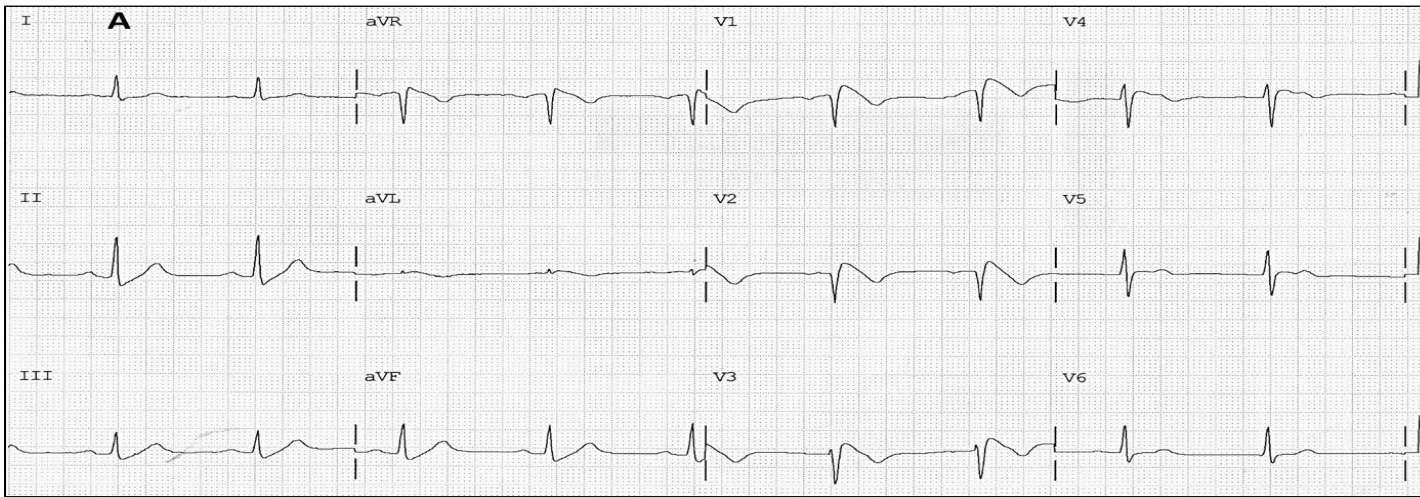


Fig. 1. Classical Brugada (A), early repolarization (B) ECG patterns and non-characteristic J-point elevation in V1 to V3 (C).

The Brugada pattern group showed a break at the end of the QRS loop after the ECD that resembled a “nose”, just before the onset of the T-wave loop. This “nose” pattern (Fig. 2A) was present in all type 1 BrS patients, but in none of the ER patients. In 100% of the ER group, the end of the QRS loop showed a “fish-hook” shape (Fig. 2B). J-point elevation was established by the non-coincidental onset and end of the QRS loop, as well as its resulting vector. This was called here as the “J-point vector”, with mean amplitudes of 0.147 ± 0.103 vs 0.221 ± 0.081 mV, BrS and ER respectively ($p = 0.0017$). The J-point angle was measured and showed a trend to be oriented forwardly and to the right in the BrS group, as compared with the ER group ($108.2 \pm 23.1^\circ \times 53.7 \pm 16.6^\circ$; $p < 0.0001$).

The ROC analysis established a 75° cutoff for the J-point angle, in the transverse plane, to diagnose Brugada syndrome with 93.8% sensitivity and 92.3% specificity. Finally, an important finding was that, in the majority of the patients (85.7% vs 76.9%, BrS and ER, respectively; $p = ns$), there was an absolutely normal T wave loop regarding position, orientation, duration, axis and amplitude.

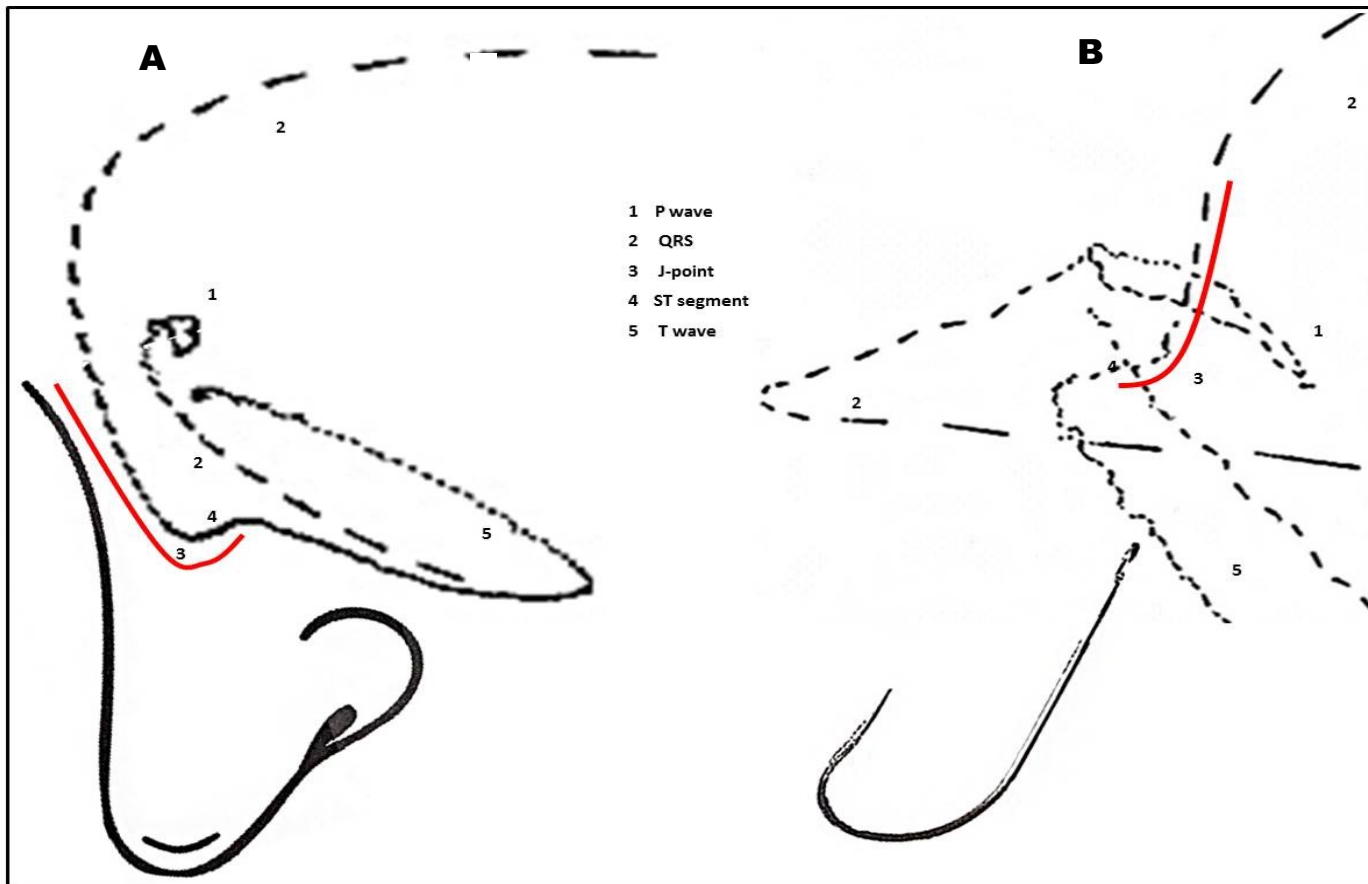


Fig. 2. QRS loops aspects: (A) Brugada nose and (B) hook shape.

Qualitative analysis of the vectorcardiograms showed a neat end-conduction delay (ECD) in all the study subjects. ECD is defined as a conduction delay greater than 10 ms at the final portion of the QRS loop in all the planes, either to the left or to the right (slowing of the “comets”, which tend to come closer and eventually to merge). In the transverse plane, QRS loops have a counterclockwise rotation and the ECD begins posteriorly and ends anteriorly; the main difference between them lays in the ECD position: right quadrant in all BrS patients (Fig. 3A), and left quadrant in all ER cases (Fig. 3B). Duration of the ECD was significantly longer in the BrS group than in the ER group ($35.0 \pm 6.5 \times 21.7 \pm 4.9$ ms; $p < 0.0001$). A greater than or equal to 30 ms ECD was 100% sensitive and $\cong 77\%$ specific of Brugada syndrome.

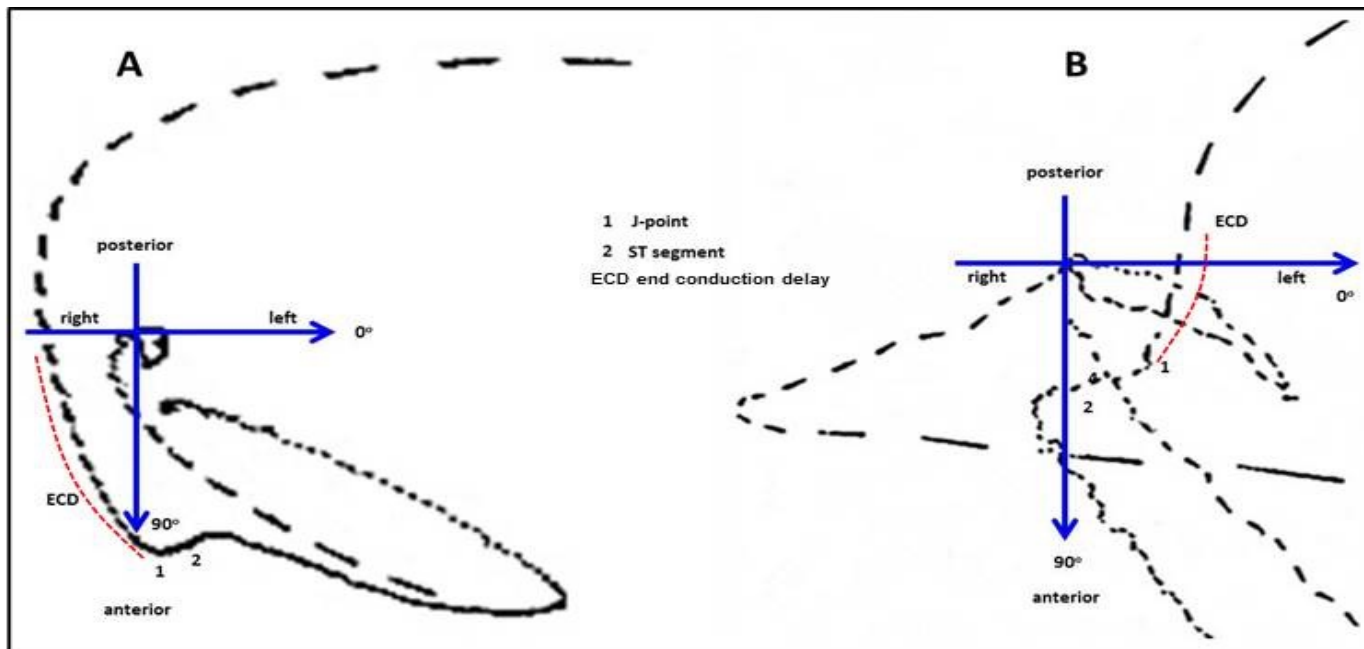


Fig. 3. Brugada syndrome (A) and early repolarization (B) end-conduction delay locations.

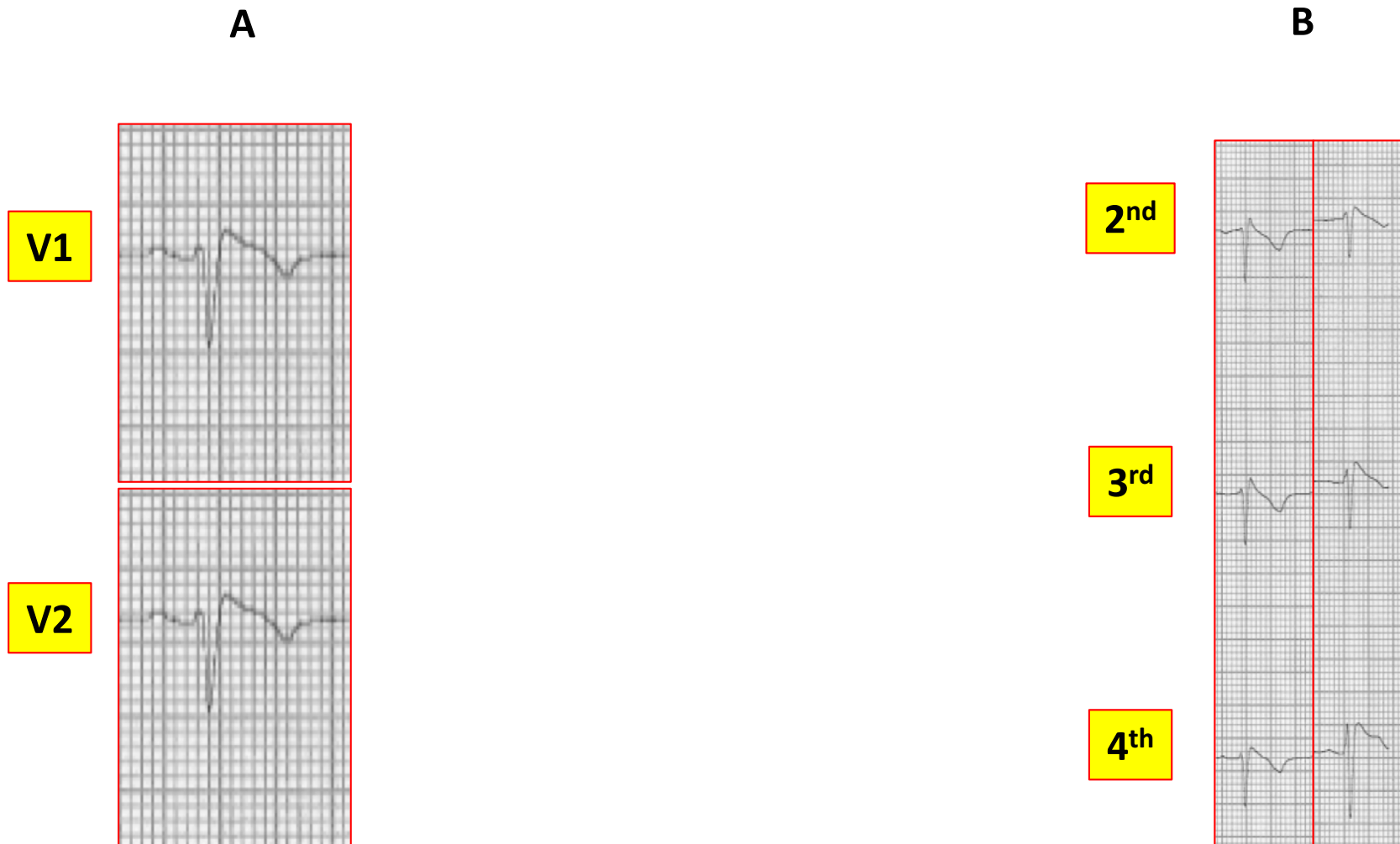We quantitatively characterized the vectorcardiographic (VCG) patterns of Brugada syndrome (BrS) and early repolarization (ER). Besides their common clinical features of young age and male gender, these entities share similar electrical and spatial aspects in VCG images, such as: a counterclockwise rotation, a marked ECD at the right ventricle, as well as a posterior-to-anterior orientation, an elevated J-point at the end of the QRS loop and a normal T wave loop. In the literature, there are similar qualitative findings in VCGs of the Brugada syndrome, such as the QRS loop rotation, the presence of a right ECD and the non-coincidental onset-end of the QRS loop. However, this study shows a posterior-to-anterior ECD orientation, instead of a posterior location. The ECD position is always located on the right side in BrS, but on the left side in ER. None of them described the Brugada “nose” or the “fish-hook” characteristic patterns at the end of the QRS loop in Brugada syndrome and early repolarization cases, respectively. These qualitative QRS loop characterizations can clearly differentiate both entities.

Brugada after RF ablation: What the vectorcardiogram can tell us?

Vectorcardiogram evaluation before and after radiofrequency (RF) catheter ablation are shown in a male patient (32 years old) with type 1 Brugada ECG (fig 4A)/ higher precordial leads (fig.4B). Before RF ablation, the VCG presented a counterclockwise rotation of the terminal segment of the QRS, with a J-point dislodgement and an ST-segment direction change (Brugada “nose” - fig.5) in the transverse plane. Immediately after RF ablation the patient presented a clear change in 12-lead (fig.6), higher precordial leads (fig.7) and VCG (fig.8), which improved in the following exams. The characteristic VCG pattern of Brugada nose disappeared just after ablation. These results suggest that the vectorcardiogram can easily detect minimal changes at the QRS/J-point/ST-segment. VCG seems to be a useful and non-invasive tool to evaluate patients with Brugada syndrome, pre- and post-radiofrequency catheter ablation.

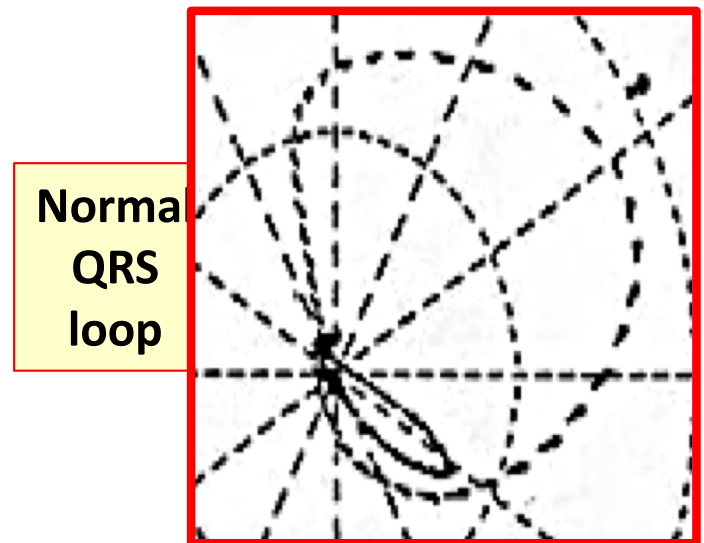
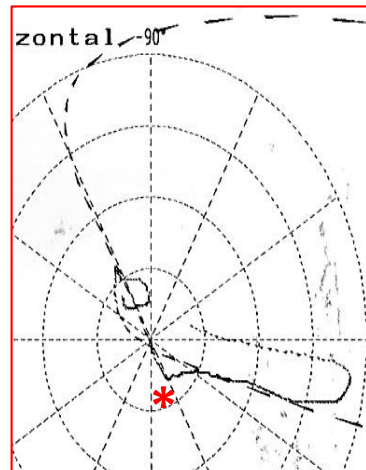
12-lead / higher precordial leads Pre RF ablation

Figure 4



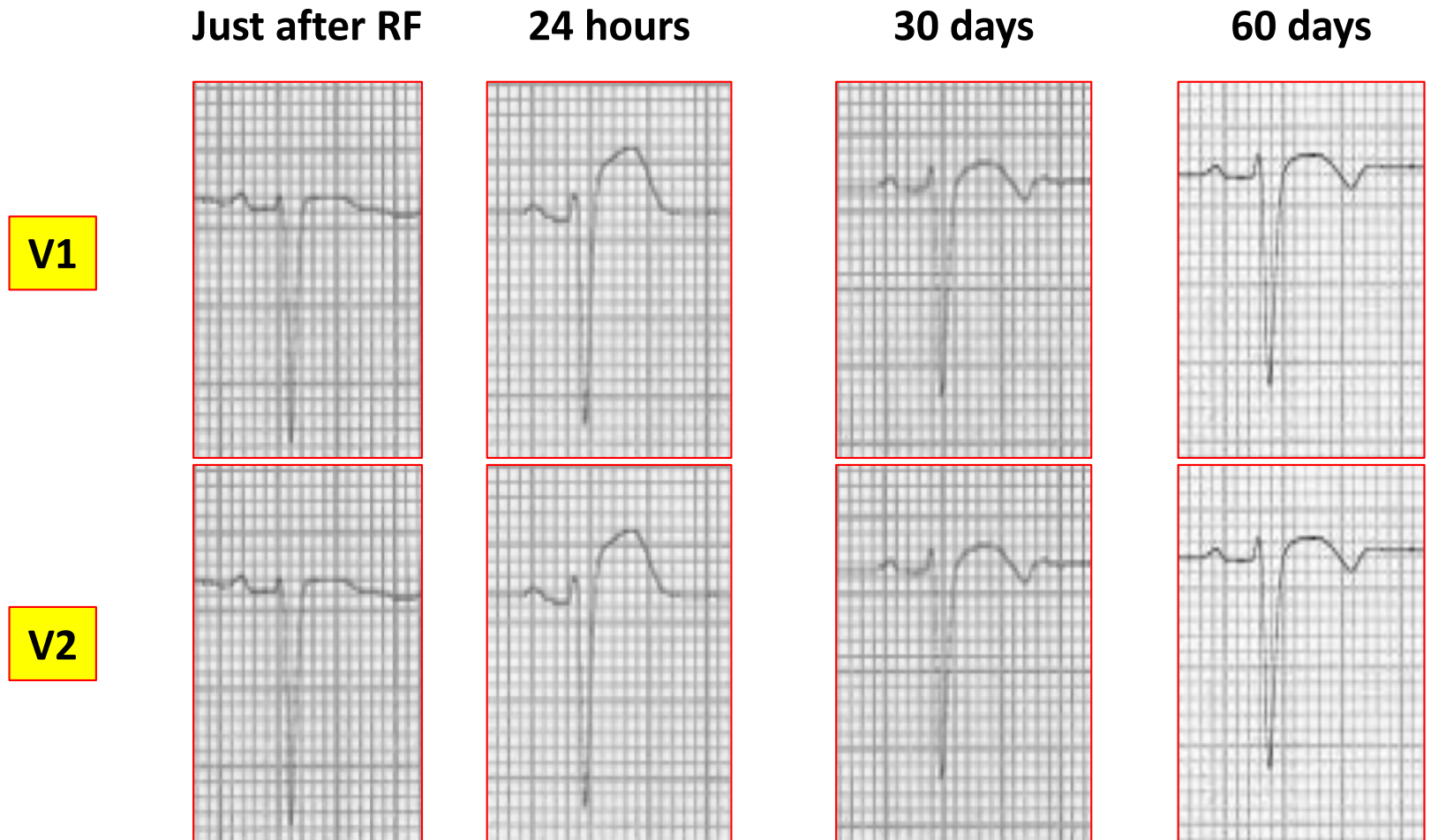
Vectorcardiogram Pre RF ablation

Figure 5



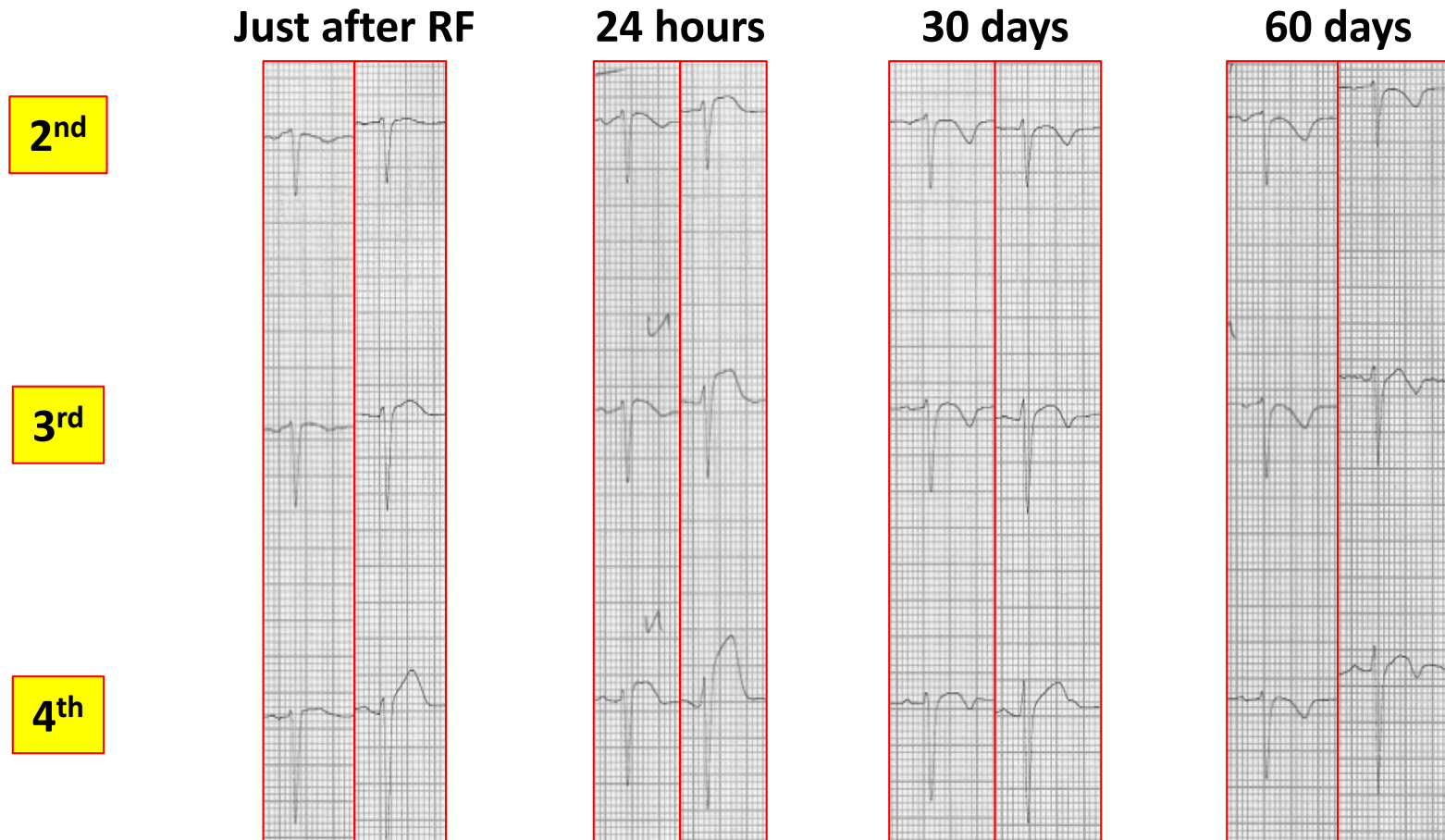
12-lead ECG After RF ablation

Figure 6



Higher precordial leads After RF ablation

Figure 7



Vectorcardiogram After RF ablation

Figure 8

